



FUE VS FUT

In Follicular Unit Transplantation, follicular units can be taken out in two ways; by Follicular Unit Strip Transplantation, the microsurgical dissection of follicular units out of a strip of donor material, and by Follicular Unit Extraction, where the follicular units are removed one at a time from the donor area. When the two techniques are compared with each other, it is often only the way in which the follicular units are removed that is compared. Nevertheless, there are other important aspects that the patient needs to consider before his treatment, such as transection percentage, transplantation quantity, healing process, etc.

Comparison of both treatment methods (FUE/FUT)

- Patient preparation

In case of a FUT treatment, the donor area after treatment is completely covered by the remaining hair, and often the transplant area is completely shaven before the treatment. For a FUE treatment, the head needs to be completely shaven. An alternative is to spread the planned FUE treatment over 2 or more sessions with at least 3 to 6 months between each session. Then macrolines will be shaved in the donor area, which are completely covered by the other hair after the treatment on the condition that the hairs at the back are at least 8cm in length or longer. There are however extra charges if we work with macrolines as it complicates the extraction of the follicular units significantly. An important disadvantage of macrolines is the miniaturization (visible thinning) in those particular lines where the follicular units have been harvested. In some cases it is possible to shave the full donor area without shaving the recipient area, it is often necessary to shave the first cm of the hairline as well. This option doesn't hinder the extraction of the follicular units so no extra costs are charged.

- Donor area

For the FUE technique, no scars remain visible to the naked eye since they shrink to only an average of 0.5mm after treatment. This technique is highly suitable for patients with a shaven or short hairstyle. With the FUT technique, in principle only a fine, linear scar remains visible, which is 1mm to 2mm wide, and which should not be visible after the treatment when the hairs are combed over it. Using the Trichophytic Closure technique, the hair can grow through the scar in order to drastically reduce the visibility of the scar. It is however important to know that some factors could influence the condition and outcome of the linear scar such as too much tension on the scar, formation of keloid or stretch-back. In such cases a scar revision should be performed to create an aesthetic result and to make the scar less noticeable.

- Quality of the hair follicles/transection percentage

Both techniques, on condition that they are carried out correctly, have in principle, a comparable quality level. The follicular units harvested with a FUE treatment are more vulnerable since they are only protected by little connecting tissue. In the hands of an experienced hair surgeon and medical team, this should however not be a problem.

- Transplant number and density

Depending on the size of the area to be treated, the average number of transplants required is between 1000 and 5000 follicular units. Hair transplants with over 5000 transplants are possible with both techniques if treatment takes place under good conditions. The required or necessary hair density of 30-70 FU/cm² is a feasible target with both techniques.





FUE VS FUT

- Healing process

With the FUE technique, the healing process goes relatively fast and is completely painless. Unlike the FUT technique, there will not be any numb feeling (of a temporary nature). On the other hand, hyperaesthesia (i.e. an enhanced sensibility of the scalp/an irritation of the nerve tissue), is a common side-effect, caused by the extraction of the follicular units, that occurs mostly 3-5 days after a FUE surgery and could cause some discomfort for the patient. Hyperaesthesia is more common in FUE mega-sessions. Whether swelling may occur in the transplant area around the forehead or the eyes really depends on the density of the follicular units per cm², as well as on the size of the area to be treated or vice versa, on the number of hair follicles to be transplanted. If swelling occurs, with both techniques this lasts about 5 to 6 days.

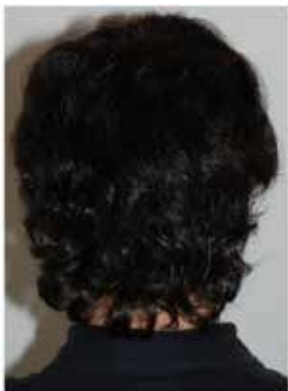- The result

The final result does not depend at all on the choice of harvesting technique (FUE or FUT) and can only be evaluated at 9 to 12 months after surgery, in some cases even after 18 months. The end result of the hair transplant does depend on the specialization and the experience of the attending surgeon, and of the skills of his medical team. Both the FUT and FUE technique should be able to be used without problems by an experienced and proficient hair surgeon, depending on the needs and indications of the patient. An equally important property for aesthetically justified end result is the shape and density of the hairline (~number of FU/cm²).

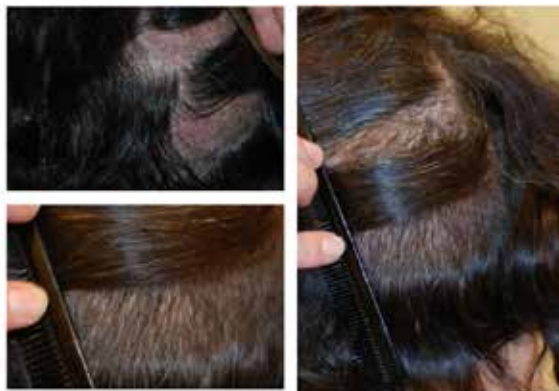Follicular Unit Extraction

Thanks to this meticulous, very labour-intensive technique, the follicular units are immediately removed intact from the donor area, without a linear incision on the back of the head. During Follicular Unit Extraction or 'FUE' treatment, the follicular units with 1, 2, 3 and 4 hairs are selectively removed, one by one, from the back of the head. In order to guarantee high return and optimal quality, the hair in the donor area is completely shaven before the treatment. This means that the doctor can measure the angle of the follicular unit exactly, and can also estimate the position of the follicular unit in relation to the hair of the head better, since are essential aspects for precise extraction. If these aspects are not respected, the follicular units cannot be removed intact, which will result in a higher transaction percentage. Only for minor FUE sessions with 100 to 600 follicular units microlines can be shaved without problems. When macrolines are being shaved we could extract up to 1500 FU per FUE session. In case of a long hair FUE it is possible to extract a maximum of 100-500 follicular units, this specific harvesting method is ideally suited for the reconstruction of small areas in female patients (f.e. after a facelift). Micro-and macrolines and long hair FUE offer an alternative for patients who do not wish to shave all their hair.

Examples of macro-strips



Donor area pre-operative



Macro strips intra-operative and 2 weeks postoperative





FUE VS FUT

- Healing process

With the FUE technique, the healing process goes relatively fast and is completely painless. Unlike the FUT technique, there will not be any numb feeling (of a temporary nature). On the other hand, hyperaesthesia (i.e. an enhanced sensibility of the scalp/an irritation of the nerve tissue), is a common side-effect, caused by the extraction of the follicular units, that occurs mostly 3-5 days after a FUE surgery and could cause some discomfort for the patient. Hyperaesthesia is more common in FUE mega-sessions. Whether swelling may occur in the transplant area around the forehead or the eyes really depends on the density of the follicular units per cm², as well as on the size of the area to be treated or vice versa, on the number of hair follicles to be transplanted. If swelling occurs, with both techniques this lasts about 5 to 6 days.

- The result

The final result does not depend at all on the choice of harvesting technique (FUE or FUT) and can only be evaluated at 9 to 12 months after surgery, in some cases even after 18 months. The end result of the hair transplant does depend on the specialization and the experience of the attending surgeon, and of the skills of his medical team. Both the FUT and FUE technique should be able to be used without problems by an experienced and proficient hair surgeon, depending on the needs and indications of the patient. An equally important property for aesthetically justified end result is the shape and density of the hairline (~number of FU/cm²).

Follicular Unit Extraction

Thanks to this meticulous, very labour-intensive technique, the follicular units are immediately removed intact from the donor area, without a linear incision on the back of the head. During Follicular Unit Extraction or 'FUE' treatment, the follicular units with 1, 2, 3 and 4 hairs are selectively removed, one by one, from the back of the head. In order to guarantee high return and optimal quality, the hair in the donor area is completely shaven before the treatment. This means that the doctor can measure the angle of the follicular unit exactly, and can also estimate the position of the follicular unit in relation to the hair of the head better, since are essential aspects for precise extraction. If these aspects are not respected, the follicular units cannot be removed intact, which will result in a higher transaction percentage. Only for minor FUE sessions with 100 to 600 follicular units microlines can be shaved without problems. When macrolines are being shaved we could extract up to 1500 FU per FUE session. In case of a long hair FUE it is possible to extract a maximum of 100-500 follicular units, this specific harvesting method is ideally suited for the reconstruction of small areas in female patients (f.e. after a facelift). Micro-and macrolines and long hair FUE offer an alternative for patients who do not wish to shave all their hair.

Examples of macro-strips



Donor area pre-operative



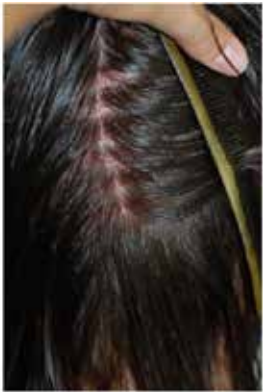Macro strips intra-operative and 2 weeks postoperative





FUE VS FUT

Examples of micro-strips



Donor area with micro strips



Micro strips in close-up




Donor area immediately postoperative

The removal of the follicular units will usually occur in 2 phases. During the first phase, a sharp punch needle (\varnothing 0.75mm to 0.90mm) is placed over the follicular unit and a circular incision is made up to half the depth of the hair follicle, and in doing this, the angle of the follicular unit is taken into account. Next, the follicular unit is detached from the soft, surrounding skin tissue. Once the follicular unit is detached, it can be removed in a second phase using one or two tweezers. Once removed, the follicular units are prepared microscopically if necessary in order to be placed afterwards in the micro-incisions in the host area. The follicular units which are removed using the FUE technique are quite delicate anatomical structures, which are only protected by a limited quantity of connecting tissue, and therefore are more susceptible to damage. Daily routine, a very precise movement and many years of microsurgical experience are absolute requirements to obtain excellent results. Due to the great precision and years of experience of Dr. Feriduni and his medical team, 3500 to 4500 follicular units can be removed in a 2 successive day session, on condition that there is sufficient donor material available.

Indications for Follicular Unit Extraction

- Patients with a mild or moderate form of alopecia (Norwood I,II and III) but nowadays FUE is also often performed on a Norwood IV and V.
- Small treatment areas such as the 'temporal peaks', eyebrows, moustache, beard, eyelashes or pubic hair.
- Reconstruction of scars after trauma, hair transplant or other surgical procedures
- Patients with insufficient or low yield of donor material
- Patients who risk severe scarring
- Patients with excessively tight scalp
- Patients with a short hairstyle
- Patients who experienced a 'bad' strip procedure
- In combination with a Follicular Unit Strip Transplantation, to guarantee the highest yield of donor material (Norwood V,VI)



FUE treatment

FUE VS FUT

Indications for Follicular Unit Extraction

- Patients with a mild or moderate form of alopecia (Norwood I,II and III) but nowadays FUE is also often performed on a Norwood IV and V.
- Small treatment areas such as the 'temporal peaks', eyebrows, moustache, beard, eyelashes or pubic hair.
- Reconstruction of scars after trauma, hair transplant or other surgical procedures
- Patients with insufficient or low yield of donor material
- Patients who risk severe scarring
- Patients with excessively tight scalp
- Patients with a short hairstyle
- Patients who experienced a 'bad' strip procedure
- In combination with a Follicular Unit Strip Transplantation, to guarantee the highest yield of donor material (Norwood V,VI)

What inconvenience is involved in FUE treatment?

- For FUE treatment, the hair is cut really short (0.9mm).
- A FUE treatment requires extreme precision and is therefore time-consuming, with the average treatment lasting between 6 and 10 hours. For this purpose, both the medical team and the patient need a significant amount of patience.

What inconvenience is involved after FUE treatment?

- At least one week of rest is recommended after a FUE treatment
- Formation of scabs up to about 5 to 6 days after the treatment
- Possible pale red coloration of the scalp up to about 2 weeks after the treatment
- Any occurrence of swelling (oedema) of the nose, eyes, forehead and/or side of the face about 2 to 3 days after the treatment; this swelling stops after a maximum of 5 to 6 days.
- On a hairless surface, after a FUE treatment, a maximum of visual or biological hair density of 30-60 FU/cm² can be achieved. Higher hair density can only be achieved by a second treatment; depending on the degree of baldness.
- Hyperaesthesia of the scalp

Healing process of the donor area

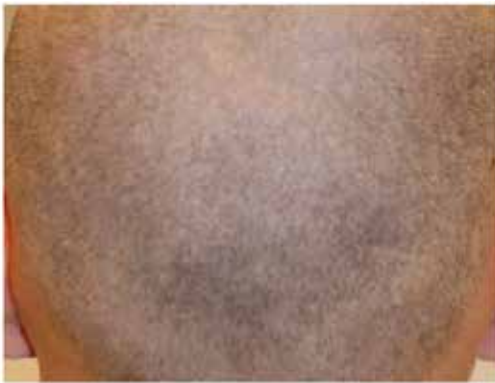It is unnecessary to stitch the small incisions of the donor area and they usually heal already after one week. All these incisions leave a small round scar, but a FUE scar is minimal and not visible with the naked eye, because it shrinks to less than 0.5mm. Many patients worry about how the donor area will look immediately after the treatment, and after how much time they will be fit to be seen by the outside world. Their main concern is often that the donor wounds will remain visible after the treatment. The photos below show the donor area before, immediately after and 10 days after the FUE treatment.



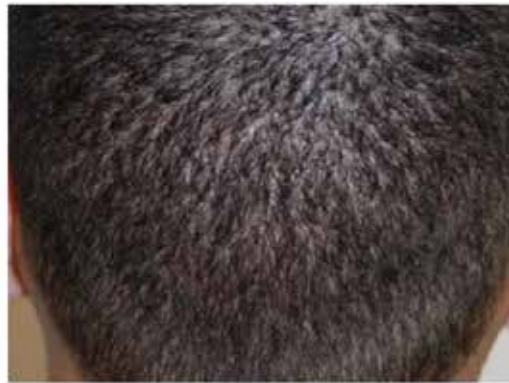FUE treatment

FUE VS FUT

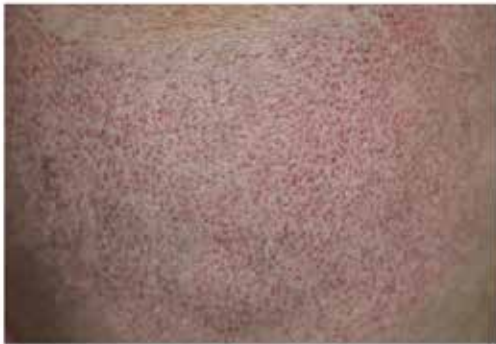These photos show that after a period of 10 days, nothing remains visible of a FUE treatment, on condition that the postoperative instructions are followed scrupulously.



Donor area before the treatment (dark hair)



Donor area 10 days after the treatment



Donor area immediately after the treatment (light hair)



Donor area 14 days after the treatment



FUE VS FUT

Indications for Follicular Unit Strip Transplantation

At present we mainly harvest follicular units by means of Follicular Unit Extraction, Follicular Unit Strip transplantation is however still not excludable in microsurgical hair restoration surgery and still regularly performed at our clinic nowadays. Follicular Unit Strip Transplantation is mostly recommended in case of:

- Male patients with long hair
- Female patients with long hair
- Older age (preferably 45+)
- Patients who had a previous strip surgery
- Patients with curly or frizzy hair
- Scar repair

What inconvenience is involved in FUT treatment?

- Before a FUT treatment, the hair is ideally shaved very short (0.9mm), some patients prefer to only shave the recipient area to 0.9mm.
- Though very seldom, complications can occur during the surgery, as is the case with any operation. These include scar pain and wound infections.

What inconvenience is involved after FUT treatment?

- At least 2 weeks of rest are recommended after a FUT treatment
- Formation of scabs up to about 5 to 6 days after the treatment
- Possible pale red coloration of the scalp up to about 2 weeks after the treatment
- Any occurrence of swelling (oedema) of the nose, eyes, forehead and/or side of the face about 2 to 3 days after the treatment; this swelling stops after a maximum of 5 to 6 days.
- The staples should be removed 2 weeks after treatment, this can be done at our clinic or by your GP or a nurse.
- A numb feeling could persist during several months after surgery (up to 1 year after surgery)



FUE VS FUT

Advantages of FUE compared with FUT or 'strip harvesting'

- No linear scar, making a short haircut possible
- Minimal invasive surgery
- Very short recovery period after the treatment
- No visible scarring
- Well suited for a tight scalp
- By means of Follicular Unit Extraction, follicular units can be removed outside the 'strip donor zone', so yield can be increased, and FUs can be taken where strip harvesting is not possible (see also 'Safe donor site management')
- FUE is well suited to fill the (wide) linear scar, even after a final FUS treatment, but particularly in the case of reconstructive treatments
- Possibility of expanding the donor area through Body Hair Transplantation (back, stomach)

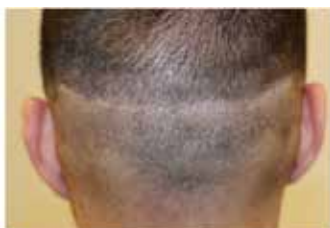Disadvantages of FUE compared with FUT or 'strip harvesting'

- The follicular units have slightly more chance of sustaining damage than with 'strip harvesting'
- Sometimes microscopic dissection is still required
- Smaller transplant numbers per treatment session
- More time-consuming and precision work ('fine trimming')
- Risk of 'moth-eaten' effect when the donor area is exhausted (after several FUE sessions or in case of low donor density)

How FUT and FUE complement each other:

As mentioned earlier, FUE can be used to remove follicular units in places that are not accessible via Follicular Unit Strip Transplantation. By combining FUE and FUT, a much higher yield can be obtained than with each of the treatment methods individually. So in the case of a Norwood 5 or 6, a combination of both techniques can be used to achieve the number of follicular units that is necessary to obtain a considerable hair density and a satisfactory result. Sometimes, after various strip treatments, a FUE treatment can be carried out to eliminate a rather wider linear scar. This can be used if, after various strip treatments, insufficient flexibility is still present at the back of the head, to apply scar correction by means of Trichophytic Closure.

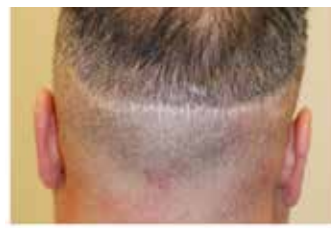Scar corrections by means of Follicular Unit Extraction



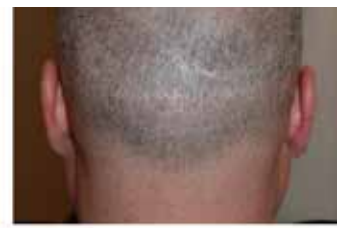Preoperative



1 year postoperative



Preoperative



1 year postoperative